



Detection of Intestinal Metaplasia among Sudanese Patients with Chronic Gastritis by Using Combined Alcian Blue-PAS Technique

Mohammed AlmosfaKamal¹, Assma Abdelwahab Ibrahim¹, Aliaa Osman Mohamadein¹ Sawsan Abdel Rahim² Ibrahim Bakhit Yousif Elemam³.
Awad Eljeed Abugooda Alobaid⁴.

¹Department of Histopathology and Cytology, Faculty of Medical Laboratory Sciences, University of Khartoum-Sudan.

²Assistant Professor, Department of Pathology, Faculty of Medicine, University of Khartoum.

³Department of Histopathology and Cytology, Faculty of Medical Laboratory Sciences, Shendi University, Sudan.

⁴Department of Histopathology and Cytology, Medical Laboratory Sciences, Al-yarmouk College, Khartoum, Sudan.

Correspondence: Mohammed Almosfa Kamal, Department of Histopathology and Cytology, Faculty of Medical Laboratory Sciences, University of Khartoum-Sudan,
E-mail: mosfa120mosfa@gmail.com

Abstract

Background and aim: Gastric cancer (GC) is one of cancer that leads to death in the world. GC is usually developed through a series of mucosal changes from non-atrophic gastritis to atrophic gastritis (AG), intestinal metaplasia (IM), dysplasia and adenocarcinoma. *Helicobacter pylori* (*H.pylori*) infection is an important initiating and promoting step of this gastric carcinogenesis. The current study conducted to identify the frequency of *H.pylori* and (IM) among Sudanese patients with Gastritis and to determine the role of combined PAS/ Alcian blue stain to detect intestinal metaplasia

Materials and methods: This retrospective study was conducted on 100 formalin fixed paraffin embedded blocks of gastric biopsies with chronic gastritis, severity of gastritis was graded.

Results: Hundred formalin fixed paraffin embedded Blocks from patients with gastritis were enrolled, of which 64 (64%) were females and 36 (36%) are males. Age range from 14 to 80 years with median age of 47. The activity of gastritis was mild in 48%, moderate in 43% and severe in 8% of cases. Intestinal metaplasia was present in 10% (10/100). Concerning *H.pylori* infection as evaluated by H&E was reported in 49% of cases, among which 69% (34/49) of patients with chronic active gastritis were positive against 31% (15/39) of non-active chronic gastritis ($p=0.000$). *H.pylori* infection was related to the severity of gastric ($p=0.01$). *H.pylori* considered to be positive in antrum more than Fundus according to the site of biopsy a ($p=0.003$).

Seven negative intestinal metaplasia observed by H&E, appear to positive when reviewed by the alcian blue combined with PAS, so the IM reported to be positive in 3% and 10% by H&E and alcian combined with PAS respectively.

Conclusion: this study concludes that *H.pylori* are most frequent cause of chronic gastritis. A significant cases of IM were detected using combination of alcian blue-PAS stain among patients with chronic gastritis.

Keywords: *Helicobacter pylori*; Gastric cancer; Intestinal metaplasia; Alcian blue and PAS.

Introduction

Gastric cancer (GC) is a major contribute to mortality worldwide ^[1]. The incidence of this cancer has declined over the past decades but is still the fourth most common cancer and second leading cause of cancer related death worldwide ^[2,3]. Gastric cancer has two types: intestinal and diffuse types. The pathogenesis of the intestinal type of gastric cancer is related to precursor lesions such as chronic atrophic gastritis, intestinal metaplasia (IM), and adenoma/dysplasia. However, the pathogenesis of the diffuse type of gastric cancer is not well defined ^[4]. Chronic gastritis, especially that associated to *Helicobacter pylori* (*H.pylori*) predisposes to the intestinal form of gastric carcinoma ^[5,6]. *H.pylori* infection is associated with severe gastritis, chronic atrophic gastritis, and IM, as well as gastric cancer ^[7,8]. Severe atrophy accompanying IM is related to a particularly high risk in *H. pylori* infected patients ^[9]. Some clinical studies reported that IM improves or did not progress after *H.pylori* eradication therapy ^[10,11]. As a result, *H.pylori* eradication is one of the most promising approaches in gastric cancer prevention ^[12]. Intestinal metaplasia of the gastric mucosa is a relatively frequent precancerous lesion for gastric cancer ^[13,5]. Intestinal metaplasia refers to the progressive replacement of the gastric mucosa by epithelium having the light and electronic microscopic features of intestinal epithelium of either small or large bowel type. Based on the cell differentiation and mucins secretion, three types of IM can be recognized in the stomach, i.e., Type 1, Type 2, and Type 3. IM has been observed in various gastric lesions such as gastric cancer, gastric ulcer, and atrophic gastritis ^[14]. Patients with gastric intestinal metaplasia (GIM) may have a greater than 10-fold increased risk of gastric

cancer than the general population. GIM is recognized as a premalignant condition that may be the result of an adaptive response to environmental stimuli such as *H pylori* infection, smoking, and high salt intake ^[15].

Materials and Methods

This study was conducted at Soba university hospital, during the period from January to December 2016. (100) formalin fixed paraffin embedded Blocks of gastric biopsies with chronic gastritis were included in this study. All blocks are cut into (3 microns) by using Leica bio system microtome. And spread in water bath then put in coated glass slides, then all sections deparaffinized in xylene and rehydrated through descending grade of alcohols, then water. All sections were stained by combined alcian blue–PAS for mucins demonstration as followed;the hydrated sections were stained in alcian blue for 15 minutes and wash with tap water, after that oxidize with periodic acid for 5 minutes and wash with deionized water, then cover the section with Schiff reagent for 30 minutes and wash in running tap water for 5 minutes. Lastly dehydrate in ascending grade of ethanol, then clear with xylene and mount with Distrene Polystyrene Xylene (DPX).

The obtained data analyzed using SPSS computer program, frequency, means; cross tabulation and chi-square values were calculated. P value <0.05 was considered as statistically significant.

Results

100 formalin fixed paraffin embedded blocks from patients previously diagnosed with gastritis

were included in the study , their age range from 14 to 80 years with medium age of 47 years, 64% were females and 36% males, as illustrated in (Fig 1)

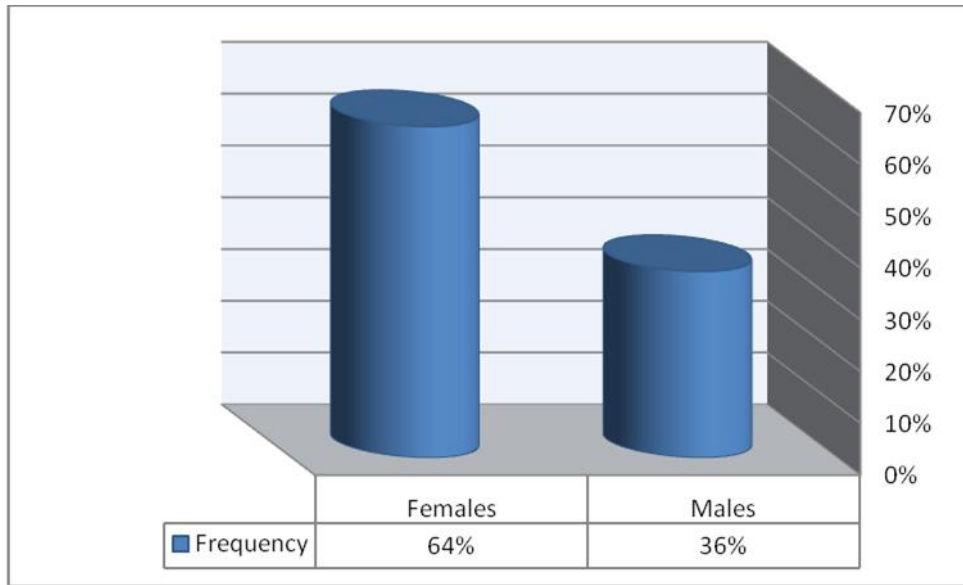


Figure 1: the frequency of the gender among study population.

Considering the degree of activity of chronic gastritis, it was mild in 48% of patients with

chronic gastritis, moderate in 43%, and severe in 8% as shown in (Fig 2).

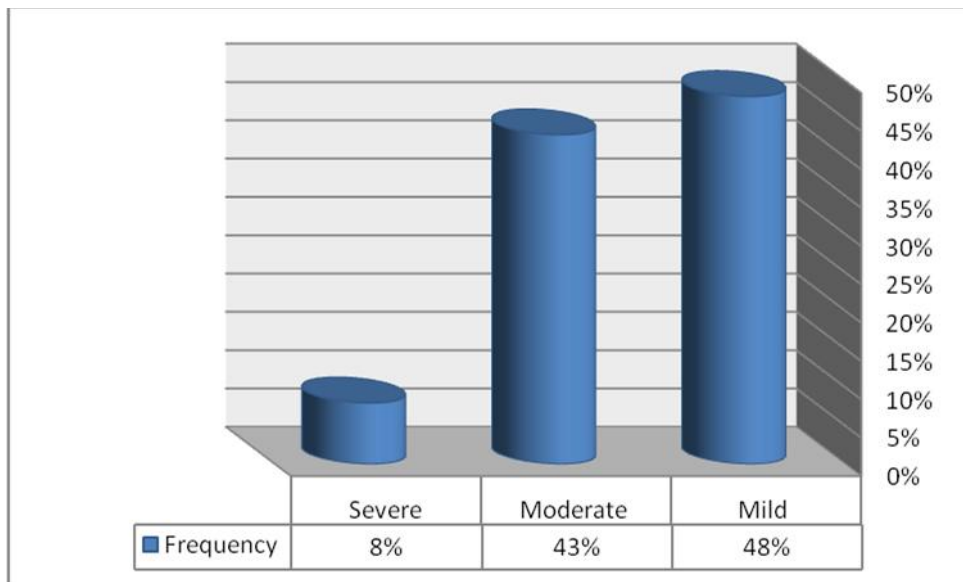


Figure 2: the frequency of the degree of activity of chronic gastritis.

Helicobacter pylori infection in chronic gastritis.

The relation between *H. pylori* infection and chronic gastritis is portrayed on (Fig 3), 49% of patients with chronic gastritis were *H. pylori* positive against 51% who were *H. pylori* negative, among which 69% (34/49) of patients with chronic active gastritis were positive

against 31% (15/49) of non-active gastritis (p = 0.000) as shown in (Table 1). The activity of chronic gastritis was mild in 48%, moderate in 43% and severe in 8% of cases, and the severity of chronic gastritis was related to the presence of *H. pylori* infection (p = 0.01), as demonstrated in (Table 2). 10% of gastric intestinal metaplasia were reported in patients with chronic gastritis as described in (Fig 4).

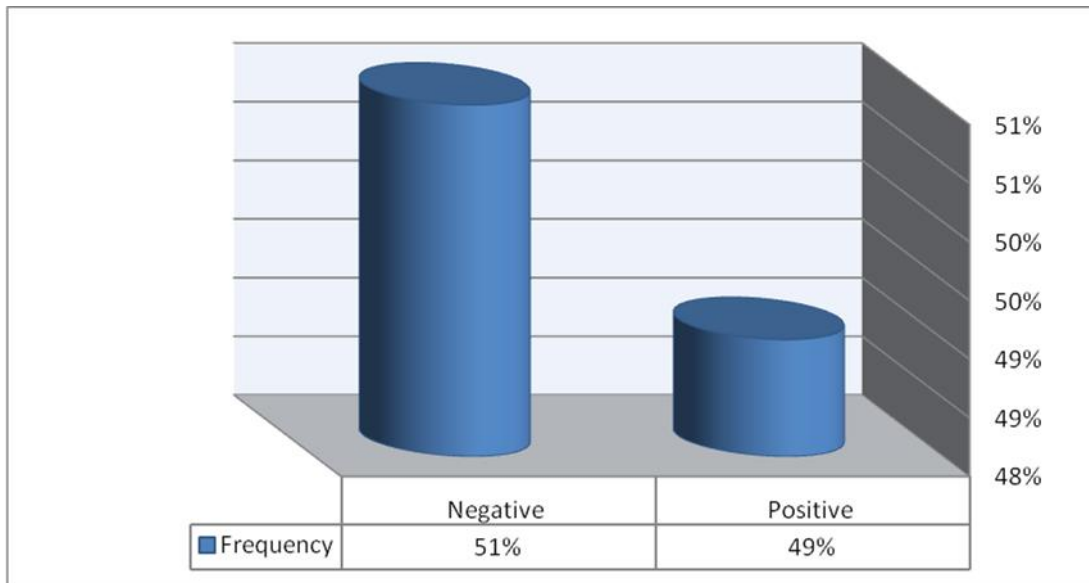


Figure 3: the frequency of *H.pylori* infection among study population.

Table 1: the frequency of *H.pylori* infection according to the activity of gastritis

Gastritis	<i>H. pylori</i> results		Total	p. value
	Positive	Negative		
Active	34	5	39	0.00
Non active	15	46	61	
Total	49	51	100	

Table 2: the frequency of *H.pylori* infection according to the severity of gastritis

Severity of Gastritis	<i>H. pylori</i> results		Total	p. value
	Positive	Negative		
Mild	15	34	49	0.01
Moderate	29	14	43	
Severe	05	03	08	
Total	49	51	100	

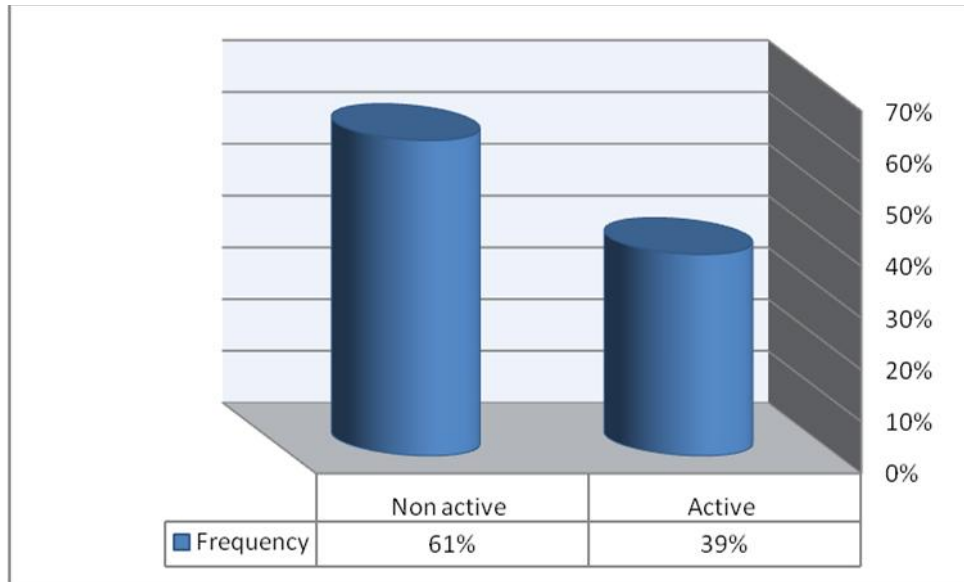


Figure 4: the frequency of the activity of chronic gastritis.

The correlation between *H.pylori* infection and the site of biopsy.

H pylori considered to be positive in antrum more than Fundus according to the site of biopsy a ($p = 0.003$), as demonstrated in (Table 3). The frequency of intestinal metaplasia of the stomach

with respect to age and gender in gastritis. Seven negative intestinal metaplasia observed by H&E, appear to positive when reviewed by the alcian blue combined with PAS, so the IM reported to be positive in 3% and 10% and alcian combined with PAS respectively as demonstrated in (Fig 5).

Table 3: the frequency of *H.pylori* infection according to the site biopsy

Site of biopsy	<i>H. pylori</i> results		Total	p. value
	Positive	Negative		
Funus	14	30	44	0.003
Antrum	31	15	46	
Both	04	06	10	
Total	49	51	100	

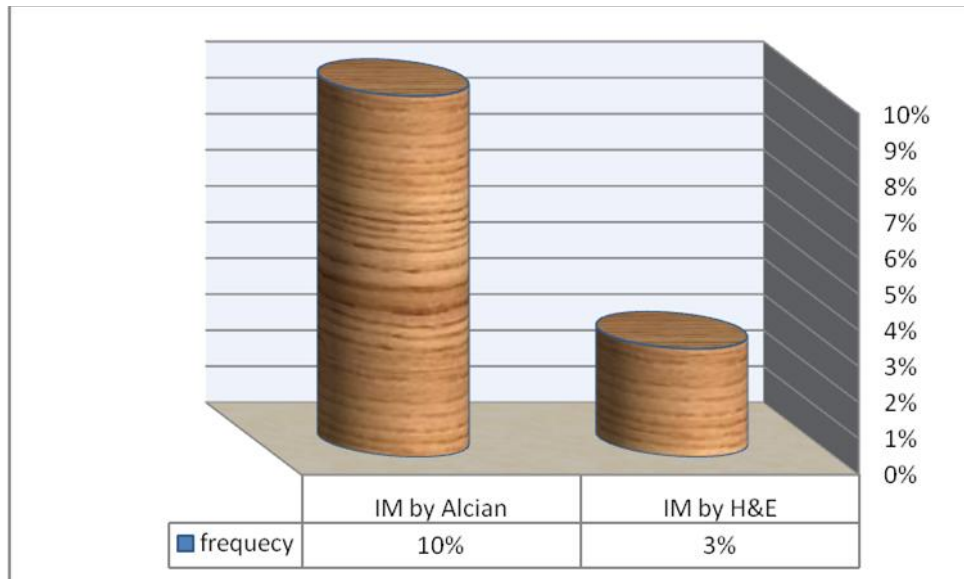


Figure 5: Comparison between H&E and alcian –PAS in the intestinal metaplasia.

Discussion

In the model of gastric carcinogenesis, *H.pylori* plays a pivotal role in causing chronic active gastritis. Chronic *H.pylori* induces gastritis and may progress over years through the sequential stages of atrophic gastritis, IM, and dysplasia to gastric adenocarcinoma [16,5]. An important risk factor for gastric cancer development is the presence of premalignant changes of the gastric mucosa, such as IM, atrophy, and dysplasia [7,12,17].

In Sudan, information about the prevalence of *H.pylori* infection is very patchy. and there is only one study which showed high prevalence (80%) of *H.pylori* infection among patients with symptoms of gastritis, 56% with duodenal ulcer, while 60% with duodenitis and 16% apparently look normal [18].

The prevalence of gastric IM and atrophy in the general population is known to vary around the globe, mostly depending on *H.pylori* status [19,20]. IM is a well-known risk factor for the development of gastric cancer [17,20]. Diagnosis of atrophic gastritis, IM, and dysplasia is often ignored in routine clinical practice [21].

According to some authors, complete IM is associated with a lower risk of gastric cancer; therefore, in the absence of other risk factors for gastric cancer, patients with complete IM do not need long-term endoscopic surveillance [22]. Due to the high prevalence of gastric cancer and *H.pylori* infection in our region, we strongly recommend endoscopic surveillance of gastric IM without paying attention to subtype.

In our study the frequency of gastric IM was 10%. The prevalence of gastric IM in the general population remains difficult to ascertain due to the asymptomatic nature of the lesion. There is a wide variation in the prevalence of gastric IM depending on the different methods used in studies and particularly the prevalence of *H.pylori* infection in the region. [20,23]. Sonnenberg et al. conducted a large retrospective study of 78,985 patients undergoing EGD with biopsy across the United States and found that the prevalence of gastric IM was 7% [24].

In our study, we observed that gastric IM was higher in older than in younger patients. Several studies revealed that age 50 years was an independent risk factor for IM, which is consistent with previous studies reporting that the incidence of IM increases with age [25,24,5].

The positive rate of *H.pylori* infection in Chronic gastritis lesions in Sudan was 49%, also the results of this study indicated that *H. Pylori* infection is associated to the severity of chronic gastritis (P value was 0.01). Globally, *H.pylori* infection is responsible for 80% of atrophic gastritis and is related to the development of precancerous conditions of the stomach and their progression to carcinoma [26, 28, 29,30]. The association between *H.pylori* infection and atrophic gastritis or intestinal metaplasia increases the risk of gastric cancer to five - six-fold [27,31]. *H.pylori* infection is both related to the severity of histological lesions and the activity of chronic antral gastritis [28, 31,32].

Regarding the comparison between H&E and combined alcian blue–PAS in the diagnoses of IM among chronic gastritis biopsies, the last technique appear to be more sensitive, as alcian blue was reactive with all IM.

In conclusion; Routine and combined alcian blue with periodic acid Schiff reagent are recommended for the detection and diagnosis of IM *H.pylori* one of the most important causes of chronic gastritis as well as pre-neoplastic gastric lesions. We found that the frequency of complete types of IM was 10% in patients with chronic gastritis, which is statistically significantly with the severity and the activity of chronic gastritis.

Recommendations: Routine use of combination of Alcian blue-PAS stain in Gastric biopsies for more efficient detection of intestinal metaplasia.

Acknowledgements

This study was supported by histopathology staff of Soba University Hospital. The authors would like to thank Dr. **Mahmoud Ibrahim Osman** and Dr. **Hisham Mohamed Ahmed**. For assistance and proofreading of the manuscript.

References

1. Asombang AW¹, Kelly P. Gastric cancer in Africa: what do we know about incidence and risk factors. *Trans R Soc Trop Med Hyg.* 2012 Feb;106(2):69-74. doi: 10.1016/j.trstmh.2011.11.002. Epub 2011 Dec 1.
2. J. Ferlay, H.-R. Shin, F. Bray, D. Forman, C. Mathers, and D. M. Parkin, "Estimates of worldwide burden of cancer in 2008: GLOBOCAN2008," *International Journal of Cancer*, vol. 127, no. 12, pp. 2893–2917, 2010.
3. A. Ferro, B. Peleteiro, M. Malvezzi et al., "Worldwide trends in gastric cancer mortality (1980–2011), with predictions to 2015, and incidence by subtype," *European Journal of Cancer*, vol. 50, no. 7, pp. 1330–1344, 2014.
4. D. Y. Park, A. Srivastava, G. H. Kim et al., "CDX2 expression in the intestinal-type gastric epithelial neoplasia: frequency and significance," *Modern Pathology*, vol. 23, no. 1, pp. 54–61, 2010.
5. Correa P. Human gastric carcinogenesis: a multistep and multifactorial process: First american cancer society award lecture on cancer epidemiology and prevention. *Cancer Res.* 1992; 52(24):6735-40.
6. Kuipers EJ. Review article: exploring the link between *Helicobacter pylori* and gastric cancer. *Aliment Pharmacol Ther.* 1999; 13
7. International Agency for Research on Cancer, Schistosomes, Liver Flukes and *Helicobacter Pylori*, IACR, Lyon, France, 1994.
8. V. Catalano, R. Labianca, G. D. Beretta, G. Gatta, F. de Braud, and E. Van Cutsem, "Gastric cancer," *Critical Reviews in Oncology/Hematology*, vol. 71, no. 2, pp. 127–164, 2009.
9. Uemura, S. Okamoto, S. Yamamoto et al., "Helicobacter pylori infection and the development of gastric cancer," *The New England Journal of Medicine*, vol. 345, no. 11, pp. 784–789, 2001.
10. K. Satoh, K. Kimura, T. Takimoto, and K. Kihira, "A followup study of atrophic gastritis and intestinal metaplasia after eradication of *Helicobacter pylori*," *Helicobacter*, vol. 3, no. 4, pp. 236–240, 1998.

11. Y.-C. Lee, T. H.-H. Chen, H.-M. Chiu et al., "The benefit of mass eradication of *Helicobacter pylori* infection: a community-based study of gastric cancer prevention," *Gut*, vol. 62, no. 5, pp. 676–682, 2013.
12. M. Dinis-Ribeiro, M. Areia, A. C. de Vries et al., "Management of precancerous conditions and lesions in the stomach (MAPS): guideline from the European Society of Gastrointestinal Endoscopy (ESGE), European Helicobacter Study Group (EHS), European Society of Pathology (ESP), and the Sociedade Portuguesa de Endoscopia Digestiva (SPED)," *Virchows Archiv*, vol. 460, no. 1, pp. 19–46, 2012.
13. Correa P, Piazuelo MB, Wilson KT. Pathology of Gastric Intestinal Metaplasia: Clinical Implications. *Am J Gastroenterol*. 2010 March; 105(3): 493–498. doi:10.1038/ajg.2009.728.
14. Einstien D, Prathiba A, Parijatham B. *Et al.* Role of Mucin Histochemistry in Gastric Mucosal Lesions. *International Journal of Scientific Study*. 2016; vol 4(no 8): DOI: 10.17354/ijss/2016/587.
15. John A. Krishnavel V. Dayna S. *Et al.* The role of endoscopy in the management of premalignant and malignant conditions of the stomach. *GASTROINTESTINAL ENDOSCOPY*. Vol 82, No. 1: 2015.
16. L. Fuccio, R. M. Zagari, M. E. Minardi, and F. Bazzoli, "Systematic review: *Helicobacter pylori* eradication for the prevention of gastric cancer," *Alimentary Pharmacology and Therapeutics*, vol. 25, no. 2, pp. 133–141, 2007.
17. A. C. de Vries, N. C. T. van Grieken, C. W. N. Looman et al., "Gastric cancer risk in patients with premalignant gastric lesions: a nationwide cohort study in the Netherlands," *Gastroenterology*, vol. 134, no. 4, pp. 945–952, 2008.
18. Elbagir M, Ahmed K (2001) Duodenal ulcer in Sudan. *Sudan Medical Journal* 24: 1-39.
19. N. Uemura, S. Okamoto, S. Yamamoto et al., "*Helicobacter pylori* infection and the development of gastric cancer," *the new England Journal of Medicine*, vol. 345, no. 11, pp. 784–789, 2001.
20. A. C. de Vries, J. Haringsma, and E. J. Kuipers, "The detection, surveillance and treatment of premalignant gastric lesions related to *Helicobacter pylori* infection," *Helicobacter*, vol. 12, no. 1, pp. 1–15, 2007. *Gastroenterology Research and Practice*
21. L. G. Capelle, A. C. de Vries, J. Haringsma et al., "The staging of gastritis with the OLGA system by using intestinal metaplasia as an accurate alternative for atrophic gastritis," *Gastrointestinal Endoscopy*, vol. 71, no. 7, pp. 1150–1158, 2010.
22. P. Correa, M. B. Piazuelo, and K. T. Wilson, "Pathology of gastric intestinal metaplasia: clinical implications," *American Journal of Gastroenterology*, vol. 105, no. 3, pp. 493–498, 2010.
23. A. Zullo, C. Hassan, A. Romiti et al., "Follow-up of intestinal metaplasia in the stomach: when, how and why," *World Journal of Gastrointestinal Oncology*, vol. 4, no. 3, pp. 30–36, 2012.
24. A. Sonnenberg, R. H. Lash, and R. M. Genta, "A national study of *Helicobacter pylori* infection in gastric biopsy specimens," *Gastroenterology*, vol. 139, no. 6, pp. 1894.e2–1901.e2, 2010.
25. W. K. Hirota, M. J. Zuckerman, D. G. Adler et al., "ASGE guideline: The role of endoscopy in the surveillance of premalignant conditions of the upper GI tract," *Gastrointestinal Endoscopy*, vol. 63, no. 4, pp. 570–580, 2006.
26. Schmidt HM, Ha DM, Taylor EF, Kovach Z, Goh KL, Fock KM, Barrett JH, Forman D, Mitchell H. Variation in human genetic polymorphisms, their association with *H pylori* acquisition and gastric cancer in a multi-ethnic country. *J Gastroenterol Hepatol*. 2011; 26(12):1725-32.
27. Uemura N, Okamoto S, Yamamoto S, Matsumura N, Yamaguchi S, Yamakido M, Taniyama K, Sasaki N, Schlemper RJ. *Helicobacter pylori* infection and the development of gastric cancer. *N Engl J Med*. 2001; 345(11):784-9.

28. Leodolter A, Ebert MP, Peitz U. Prevalence of H pylori associated high risk gastritis for development of gastric cancer in patients with normal endoscopic findings. World J Gastroenterol. 2006; 12(34): 5509- 12.
29. Attia KA, N'driYoman T, Diomande MI, Mahassadi A, Sogodogo I, Bathaix YF, Kissi H, Serme K, Sawadogo A, ManlanKassi L. Aspects cliniques, endoscopiques et histologiques des gastriteschroniques à Helicobacter pylori en côtéd'ivoire : étude de 102 patients . Bull Soc Pathol Exot. 2001;94(1):57-70.
30. Zhang C, Yamada N, Wu YL, Wen M, Matsuhisa T, Matsukura N. Helicobacter pylori infection, glandular atrophy and intestinal metaplasia in superficial gastritis, gastric erosion, erosive gastritis, gastric ulcer and early gastric cancer. World J Gastroenterol. 2005; 11(6):791-6.
31. Sipponen P. Update on the pathologic approach to the diagnosis of gastritis, gastric atrophy, and Helicobacter pylori and its sequelae. ClinGastroenterol. 2001; 32(3):196-202.
32. Rudelli A, Vialette G, Brazier F, Seurat PL, Capron D, Dupas JL.[Helicobacter pylori and gastro-duodenal lesions in 547 young patients with upper gastrointestinal symptoms]. GastroenterolClin Biol. 1996; 20(4):379-393.

Access this Article in Online	
	Website: www.ijcrims.com
Quick Response Code	Subject: Pathology

How to cite this article:

Mohammed AlmosfaKamal, Assma Abdelwahab Ibrahim, Aliaa Osman Mohamadein, Sawsan Abdel Rahim, Ibrahim Bakhit Yousif Elemam, Awad Eljeed Abugooda Alobaid. (2017). Detection of Intestinal Metaplasia among Sudanese Patients with Chronic Gastritis by Using Combined Alcian Blue-PAS Technique. Int. J. Curr. Res. Med. Sci. 3(6): 80-88.

DOI: <http://dx.doi.org/10.22192/ijcrms.2017.03.06.011>